

# Video-assisted Thoracic Surgery for Respiratory Diseases

JMAJ 52(5): 335–340, 2009

Akinori IWASAKI\*<sup>1</sup>

## Abstract

Video-assisted thoracic surgery (VATS), concurrently with endoscopic surgery in other fields of surgery, has become an essential tool for the treatment of various respiratory diseases. Originally starting from the diagnosis of benign diseases, the use of this technique has now been expanded to include the treatment of malignant diseases. In terms of reimbursement in the national health insurance programme, VATS is given higher point units over conventional thoracotomy procedures in acknowledgement of the technical requirements and advantage of VATS. Although this has contributed to the increasing use of this technique at many medical institutions in Japan, it has created two new issues we must address, which are the training of necessary skills and ensuring of patient safety. In this respect, the Japanese Association for Chest Surgery requires the completion of association-authorized thoracoscopy seminars at least twice as a prerequisite for obtaining specialist accreditation. In order to help the understanding of VATS, this article outlines the present state and the latest developments in this field, focusing on the historical background and the diseases frequently treated with this technique, such as pneumothorax, lung tumors, and mediastinal diseases. In particular, detailed explanation was given regarding the use of VATS for small lung cancers, which are being detected at an increasing rate due to improvements made in the diagnostic imaging.

**Key words** Video-assisted thoracic surgery, Respiratory disease, Present and prospect, Indication

## Introduction

Recent innovations in medical technology have brought about dramatic changes in the diagnosis and the treatment of diseases. A typical example of this in the surgical field is the development of endoscopic surgery. In particular, video-assisted thoracic surgery (VATS) for respiratory diseases is playing an increasingly important role in various situations ranging from diagnosis to treatment. The use of thoracoscopic lobectomy, a procedure demanding advanced skill and experience, is spreading to many medical institutions in Japan, as well as in the world, mostly for the treatment of lung cancer.<sup>1</sup> As a result, there are some reports on how to introduce this lobectomy to training programs.<sup>2</sup> There are also recent reports of inno-

vative endeavors such as lobectomy using robotic surgery.<sup>3</sup> Further development of new techniques in VATS is expected in the future.

This article reviews the present state of VATS and summarizes the newest developments in this field, also providing some discussion on safety training for thoracoscopic procedures.

## Historical Background and Definitions

As quoted in many publications, the earliest known documented use of thoracoscopy is generally attributed to the Swedish physician Jacobaeus who observed the thoracic cavity using a cystoscope.<sup>4</sup> However, the appearance of the term “thoracoscopy” in much older literature suggests that the procedure in one form or

\*1 Professor, Department of Thoracic Surgery, School of Medicine, Fukuoka University, Fukuoka, Japan (akinori@fukuoka-u.ac.jp). This article is a revised English version of a paper originally published in the Journal of the Japan Medical Association (Vol.137, No.9, 2008, pages 1839–1843).

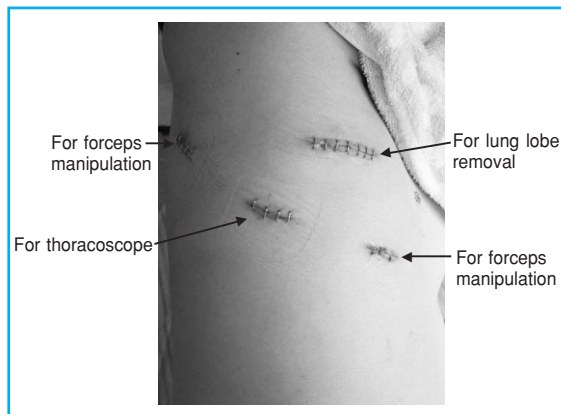


Fig. 1 VATS wounds after upper-right lobectomy

another may date back as early as to the 1800s.<sup>5</sup> Although thoracoscopy in those days is considered to have been performed with whatever faint light available, the rapid spread of thoracoscopy in recent years owes a great deal to the technological improvements made in video cameras and in light sources.

Although VATS may be combined with minimal thoracotomy depending on the nature of disease, it is basically performed by the surgeon while looking at a video monitor under thoracoscopic guidance, without using a rib spreader. Naturally, the surgical wounds are kept minimal. To illustrate this, **Fig. 1** shows typical VATS wounds after the completion of lobectomy in lung cancer.

### Usefulness of Thoracoscopy

VATS is generally considered to be superior to thoracotomy in the assessment of subjective criteria of satisfaction such as pain, breathing difficulty, and physical functions, although the results may vary somewhat depending on the timing of postoperative assessment. VATS is also reported to facilitate faster social rehabilitation.<sup>6</sup>

### Target Diseases and the Roles of Thoracoscopy

The applications of thoracoscopy are diverse, ranging from diagnosis of some diseases to the treatment of others. **Table 1** lists the diseases with indication for VATS. Since VATS is used

Table 1 Diseases with indication for VATS

Lungs and mediastinum	Diffuse lung diseases, benign lung tumors, spontaneous pneumothorax, mediastinal tumors, pleural tumors, metastatic lung tumors, lung cancer, pleural effusion of unknown origin, pulmonary emphysema, pyothorax
Diaphragm	Atony, diaphragm rupture, hernia
Other	Cardiac tamponade, hyperhidrosis, chest injury, metastatic liver tumors

most frequently for pneumothorax, lung tumors, and mediastinal tumors, among respiratory diseases, the following will focus on these respective conditions.

### Pneumothorax

Bulla resection, which had conventionally been performed using axillary thoracotomy before the popularization of endoscopic surgery, is nowadays being conducted mostly using thoracoscopy, except for cases with extensive adhesion. In general, this procedure involves a formation of openings, one for camera insertion and two for forceps manipulation (one for holding the lesion and another for the automatic endoscopic stapler). Some specialists prefer methods involving bulla ligation or coagulative cauterization, but these methods are not widely accepted.

Many of the patients with pneumothorax are young. As such, the aesthetic advantage derived from a small size of incisions, relative lack of postoperative pain, and the simplicity of procedures are all contributing to the popularity of this treatment compared with the use of thoracoscopy in other diseases.<sup>7</sup> Some reports recommend VATS over conservative therapy in the initial treatment, considering the potential for economic losses from later relapse.<sup>8</sup>

Although there is no age limit to the indication for thoracoscopy, pneumothorax in aged patients tends to accompany emphysematous changes and adhesion. Cases without extensive adhesion can be treated using thoracoscopy, but outcomes suggest a slightly increased rate of

**Table 2** Criteria for indication of VATS for liver cancer

(Lobectomy)
1. There is no significant insufficient lobulation.
2. There is no extensive adhesion.
3. The patient has cardiopulmonary functions capable of differential lung ventilation.
4. T1 ( $\leq 3$ cm) non-small cell lung cancer in peripheral lung field.
5. N0 in clinical diagnostic imaging.
6. Sufficient informed consent is obtained.
(Segmental resection)
In addition to the above, the tumor is 1 cm or smaller and located sufficiently away from the segmental partition.

(Department of Surgery, Fukuoka University School of Medicine)

prolonged air leak. VATS is associated with the pneumothorax relapse rate of 4–16%, somewhat higher than that of thoracotomy.<sup>9,10</sup> The causes of this problem may include an insufficient resection of affected tissues, an insufficient facilitation of pleural adhesion, and a formation of new bullae due to fragile pleura near the site of resection and suturing. Several methods to lower the relapse rate have been attempted, including reinforcement of pleura at bulla resection edges and surroundings.<sup>11</sup> There is also a method used in Western countries, which involves peeling of parietal pleura to achieve extensive adhesion in the apical segment and intentionally sprinkling an adhesion agent at the end of operation, is reported to lower the relapse rate. However, this method is hardly used in Japan.

### Lung tumors

Benign lung tumors are treated by partial resection as a rule, and this procedure can be performed easily under thoracoscopic guidance. In the case of lung hamartoma, even enucleation can be performed using thoracoscopy. Metastatic lung tumors are good targets of VATS as long as they are located near the visceral pleura, intraoperative identification of lesions is possible, and if there are only a few tumors in a patient. Good outcomes have also been reported for colon cancer and other nodular tumors.<sup>12</sup>

There has been more controversy about the indication of VATS for lung cancer compared with other respiratory diseases. An important reference is “Evidence-Based Clinical Practice Guidelines

for Lung Cancer, 2005 Version” (Japan Lung Cancer Society, ed.) Chapter 4, Section 4, “VATS.”<sup>13</sup> Currently, there is no large-scale randomized prospective study comparing thoracotomy and thoracoscopy in lung cancer.

However, as seen from many recent reports, there is little dispute about the indication of VATS for early-stage lung cancer. Japan’s health insurance programme specifies the reimbursement of 58,000 points for thoracoscopic lobectomy, as compared with 36,900 points for lobectomy using thoracotomy. This difference is considered to be an acknowledgement of the technical requirements and the advantages of VATS. As such, this technique is being performed at many medical institutions throughout Japan.<sup>14</sup>

**Table 2** summarizes the criteria for the use of VATS on lung cancer in our department. Generally speaking, this procedure seems to be suitable for lung cancer with a smaller diameter and a higher degree of differentiation. Because even small lung cancer with a diameter of 1 cm or less is reported to accompany lymph node metastasis at a rate of nearly 10%,<sup>15</sup> lymph node dissection should be performed even in the case of VATS. In our survey, the number of resected lymph nodes obtained through VATS lobectomy was the same as that of thoracotomy.<sup>16</sup> The percentage of lymph nodes left unremoved after lung cancer surgery using VATS is reported to be 2% in number and 3% in tissue mass.<sup>17</sup> These facts indicate that the lymph node resection in a clinical Stage I lung cancer is technically possible. The switch to thoracotomy took place in up to approximately 11% of cases.<sup>18</sup> The occurrence of complications is approximately 9% in the reports from Japan,<sup>19</sup> which are mostly pneumonia and air leak, presenting a similar profile to that after thoracotomy.

Operation-related deaths occur at a rate of 0.5–1% according to recent reports.<sup>19,20</sup> The causes of death include mesenteric vein thrombosis, pneumonia, and postoperative acute respiratory insufficiency, among others.<sup>18</sup> The rate of cancer relapse after VATS shows no difference from that of thoracotomy.<sup>21</sup> The prognosis is similar to that after standard thoracotomy in many reports. The 5-year survival rate in clinical Stage IA is 90% after VATS, which is not much different from 85% after thoracotomy.<sup>22</sup> When analysis is limited to pathological Stage IA, the rate becomes as good as 92.4%.<sup>23</sup> The survival

rate at pathological Stage IA in our department is 90.9%, and we also reported excellent results of segmental resection by VATS.<sup>24</sup> Houck et al. performed left-upper segmental resection by VATS in limited operation on Stage I lung cancer and reported a lack of relapse during the mean observation period of 13.5 months.<sup>25</sup>

In recent years, it has become possible to grasp the approximate tumor morphology preoperatively using high-resolution CT, and there has been some discussion regarding the indication of limited operation for small highly-differentiated adenomas presenting ground glass opacity (GGO).<sup>26,27</sup> Future development may make it possible to perform procedures such as partial resection using VATS, at least in appropriately selected patients.

### Mediastinal tumors

Although resection is a useful method to treat benign mediastinal tumors, however, operations in the mediastinum require special attention to the risk of damage to surrounding organs.

Among cystic tumors, the main target diseases include tracheal cysts, pericardial cysts, and thymic cysts.<sup>28,29</sup> Tumors containing cysts like these must be treated with extra care to prevent leakage of cyst content due to capsule damage.<sup>30</sup> Neurogenic tumors most frequently originate from intercostal nerves and sympathetic nerves, and these can be removed by thoracoscopic resection.<sup>31</sup> This procedure, however, is not suitable for tumors with large diameters. Although opinions about thymoma differ among specialists, many institutions consider that VATS is indicated for Stage I thymoma in Masaoka's classification. For myasthenia gravis, VATS compares favorably to median sternotomy in that nearly complete resection of thymic tissues is possible, and the clinical efficacy is also comparable. This method can be first-line therapy particularly for young female patients from an aesthetic standpoint.

### VATS for Other Respiratory Diseases

Procedures such as bullectomy using an automatic stapler for gigantic lung cysts and lung volume reduction surgery (LVRS) for pulmonary emphysema have become well-established. These include thoracoscopic LVRS for pulmonary emphysema, which can improve breathing difficulty and QOL as a result of improvement in

respiratory function. A recent report supported the use of surgical treatment in patients considered for resection of low attenuation area (LAA) with bilateral upper lobe dominance.<sup>32</sup>

For cardiac tamponade accompanying the symptoms of pericarditis, dramatic improvement of symptoms can be achieved through incisions into the pericardium at positions anterior and posterior to the phrenic nerve, spanning several centimeters each, allowing the effusion of pericardial fluid and the releasing of pressure.<sup>33</sup> In addition, when other tests and examinations fail to give a diagnosis, this technique is the most effective means for identifying the cause of pleural effusion of unknown origin and making definitive diagnosis of diffuse lung diseases.<sup>34</sup>

VATS is indicated for diffuse lung diseases when diagnosis is not achieved by transbronchial lung biopsy (TBLB) and bronchial alveolar lavage (BAL). However, recent trends show a decrease in the use of VATS in cases where diagnosis can be made from imaging and clinical findings. For definitive diagnosis, it is desirable to perform resection at multiple locations (sites with strong, intermediate, and weak signs of pathological changes). As the cause of the pleural effusion of unknown origin is identified easily on sites including the dorsal thorax and diaphragm, the examination is focused on these sites. This technique is extremely useful for the diagnosis of mesothelioma, which is a pleural disease attracting much attention recently, as well as plaque formation.<sup>35</sup>

Aside from lung diseases, thoracic sympathetic nerve resection for palm hyperhidrosis is also a technique performed with thoracoscopy. Details of the procedure, such as the site of resection, are changing with times, reflecting the effort to minimize compensatory perspiration. Thoracoscopy is also used in the diaphragmatic approach to diaphragmatic diseases and liver tumors. In infectious respiratory diseases, thoracoscopy may be used for ensuring accurate positioning of a drainage tube for pus removal in acute pyothorax, for performing lavage to reduce bacterial mass, and in particular for removing fibrous capsules and performing lung expansion manipulation.<sup>36</sup> In addition, thoracoscopy may be effective in the observation of a diaphragm rupture and intrathoracic conditions in the cases with chest injury, providing valuable information for the determination of treatment strategies and approach selection.<sup>37</sup>

## Conclusion

As discussed above, thoracoscopic surgery is a useful means for the diagnosis and the treatment of various respiratory diseases. As a result, training in thoracoscopic surgery has become as important as other fields of endoscopic surgery. The questionnaire survey conducted by the Japan Society for Endoscopic Surgery in 2006 identified the occurrence of serious events such as blood

vessel damage<sup>14</sup> and considering an incident as this, surgeons must strive to improve their technical skills and patient safety in operations. The Japanese Association for Chest Surgery demands the completion of association-authorized thoracoscopy seminars at least twice as a prerequisite for obtaining a specialist accreditation. Actions towards improving skills and patient safety for VATS will become all the more important in the future.

## References

- McKenna RJ Jr, Houck W, Fuller CB. Video-assisted thoracic surgery lobectomy: experience with 1,100 cases. *Ann Thorac Surg.* 2006;81:421–425.
- Reed MF, Lucia MW, Starnes SL, et al. Thoracoscopic lobectomy: introduction of a new technique into a thoracic surgery training program. *J Thorac Cardiovasc Surg.* 2008;136:376–381.
- Park BJ, Flores RM, Rusch VW. Robotic assistance for video-assisted thoracic surgical lobectomy: technique and initial results. *J Thorac Cardiovasc Surg.* 2006;131:54–59.
- Jacobaeus HC. Ueber die Möglichkeit die Zystoskopie bei Untersuchung seröser Höhlungen anzuwenden. *Munch Med Wochenschr.* 1910;57:2090–2092.
- Hoksch B, Birken-Bertsch H, Müller JM. Thoracoscopy before Jacobaeus. *Ann Thorac Surg.* 2002;74:1288–1290.
- Li WW, Lee TW, Lam SS, et al. Quality of life following lung cancer resection: video-assisted thoracic surgery vs thoracotomy. *Chest.* 2002;122:584–589.
- Sedrakyan A, van der Meulen J, Lewsey J, et al. Video assisted thoracic surgery for treatment of pneumothorax and lung resections: systematic review of randomised clinical trials. *BMJ.* 2004;329:1008.
- Morimoto T, Shimbo T, Noguchi Y, et al. Effects of timing of thoracoscopic surgery for primary spontaneous pneumothorax on prognosis and costs. *Am J Surg.* 2004;187:767–774.
- Naunheim KS, Mack MJ, Hazelrigg SR, et al. Safety and efficacy of video-assisted thoracic surgical techniques for the treatment of spontaneous pneumothorax. *J Thorac Cardiovasc Surg.* 1995;109:1198–1203.
- Sawada S, Watanabe Y, Moriyama S. Video-assisted thoracoscopic surgery for primary spontaneous pneumothorax: evaluation of indications and long-term outcome compared with conservative treatment and open thoracotomy. *Chest.* 2005;127:2226–2230.
- Sakamoto K, Takei H, Nishii T, et al. Staple line coverage with absorbable mesh after thoracoscopic bullectomy for spontaneous pneumothorax. *Surg Endosc.* 2004;18:478–481.
- Mutsaerts EL, Zoetmulder FA, Meijer S, et al. Long term survival of thoracoscopic metastasectomy vs metastasectomy by thoracotomy in patients with a solitary pulmonary lesion. *Eur J Surg Oncol.* 2002;28:864–868.
- The Japan Lung Cancer Society. Evidence Based Clinical Practice Guidelines for Lung Cancer, 2005 Version. Tokyo: Kanehara & Co., Ltd.; 2005. (in Japanese)
- Japan Society for Endoscopic Surgery. Questionnaire survey regarding endoscopic surgery, report of the results of the 8th compilation of data. *Journal of Japan Society for Endoscopic Surgery.* 2006;11:575–583. (in Japanese)
- Miller DL, Rowland CM, Deschamps C, et al. Surgical treatment of non-small cell lung cancer 1 cm or less in diameter. *Ann Thorac Surg.* 2002;73:1545–1550.
- Iwasaki A, Shirakusa T, Kawahara K, et al. Is video-assisted thoracoscopic surgery suitable for resection of primary lung cancer? *Thorac Cardiovasc Surg.* 1997;45:13–15.
- Sagawa M, Sato M, Sakurada A, et al. A prospective trial of systematic nodal dissection for lung cancer by video-assisted thoracic surgery: can it be perfect? *Ann Thorac Surg.* 2002;73:900–904.
- Walker WS, Codispoti M, Soon SY, et al. Long-term outcomes following VATS lobectomy for non-small cell bronchogenic carcinoma. *Eur J Cardiothorac Surg.* 2003;23:397–402.
- Ohtsuka T, Nomori H, Horio H, et al. Is major pulmonary resection by video-assisted thoracic surgery an adequate procedure in clinical stage I lung cancer? *Chest.* 2004;125:1742–1746.
- Gharagozloo F, Tempesta B, Margolis M, et al. Video-assisted thoracic surgery lobectomy for stage I lung cancer. *Ann Thorac Surg.* 2003;76:1009–1014.
- Thomas P, Doddoli C, Yena S, et al. VATS is an adequate oncological operation for stage I non-small cell lung cancer. *Eur J Cardiothorac Surg.* 2002;21:1094–1099.
- Sugi K, Kaneda Y, Esato K. Video-assisted thoracoscopic lobectomy achieves a satisfactory long-term prognosis in patients with clinical stage IA lung cancer. *World J Surg.* 2000;24:27–30.
- Tatsumi A, Ueda Y. Video-assisted thoracic surgery for lung cancer: is it a feasible operation for stage I lung cancer? *Jpn J Thorac Cardiovasc Surg.* 2003;51:646–650.
- Iwasaki A, Shirakusa T, Shiraishi T, et al. Results of video-assisted thoracic surgery for stage I/II non-small cell lung cancer. *Eur J Cardiothorac Surg.* 2004;26:158–164.
- Houck WV, Fuller CB, McKenna RJ Jr. Video-assisted thoracic surgery upper lobe trisegmentectomy for early-stage left apical lung cancer. *Ann Thorac Surg.* 2004;78:1858–1860.
- Nakamura H, Saji H, Ogata A, et al. Lung cancer patients showing pure ground-glass opacity on computed tomography are good candidates for wedge resection. *Lung Cancer.* 2004;44:61–68.
- Yamada S, Kohno T. Video-assisted thoracic surgery for pure ground-glass opacities 2 cm or less in diameter. *Ann Thorac Surg.* 2004;77:1911–1915.
- Japan Society for Endoscopic Surgery. Clinical Practice Guidelines for Endoscopic Surgery, 2008 Version. Tokyo: Kanehara & Co., Ltd.; 2008:152–156. (in Japanese)
- Demmy TL, Krasna MJ, Detterbeck FC, et al. Multicenter VATS experience with mediastinal tumors. *Ann Thorac Surg.* 1998;66:187–192.
- Iwasaki A, Hiratsuka M, Kawahara K, et al. New technique for the cystic mediastinal tumor by video-assisted thoracoscopy. *Ann Thorac Surg.* 2001;72:632–633.
- Hazelrigg SR, Boley TM, Krasna MJ, et al. Thoracoscopic resection of posterior neurogenic tumors. *Am Surg.* 1999;65:1129–1133.
- National Emphysema Treatment Trial Research Group. A randomized trial comparing lung-volume reduction surgery with medical therapy for severe emphysema. *N Engl J Med.* 2003;348:2059–2073.
- Georghiou GP, Stamler A, Sharoni E, et al. Video-assisted thoracoscopic pericardial window for diagnosis and manage-

- ment of pericardial effusions. *Ann Thorac Surg.* 2005;80:607–610.
34. Lee YC, Wu CT, Hsu HH, et al. Surgical lung biopsy for diffuse pulmonary disease: experience of 196 patients. *J Thorac Cardiovasc Surg.* 2005;129:984–990.
35. Nakas A, Martin Ucar AE, Edwards JG, et al. The role of video assisted thoracoscopic pleurectomy/decortication in the therapeutic management of malignant pleural mesothelioma. *Eur J Cardiothorac Surg.* 2008;33:83–88.
36. Solaini L, Prusciano F, Bagioni P. Video-assisted thoracic surgery in the treatment of pleural empyema. *Surg Endosc.* 2007;21:280–284.
37. Lowdermilk GA, Naunheim KS. Thoracoscopic evaluation and treatment of thoracic trauma. *Surg Clin North Am.* 2000;80:1535–1542.